

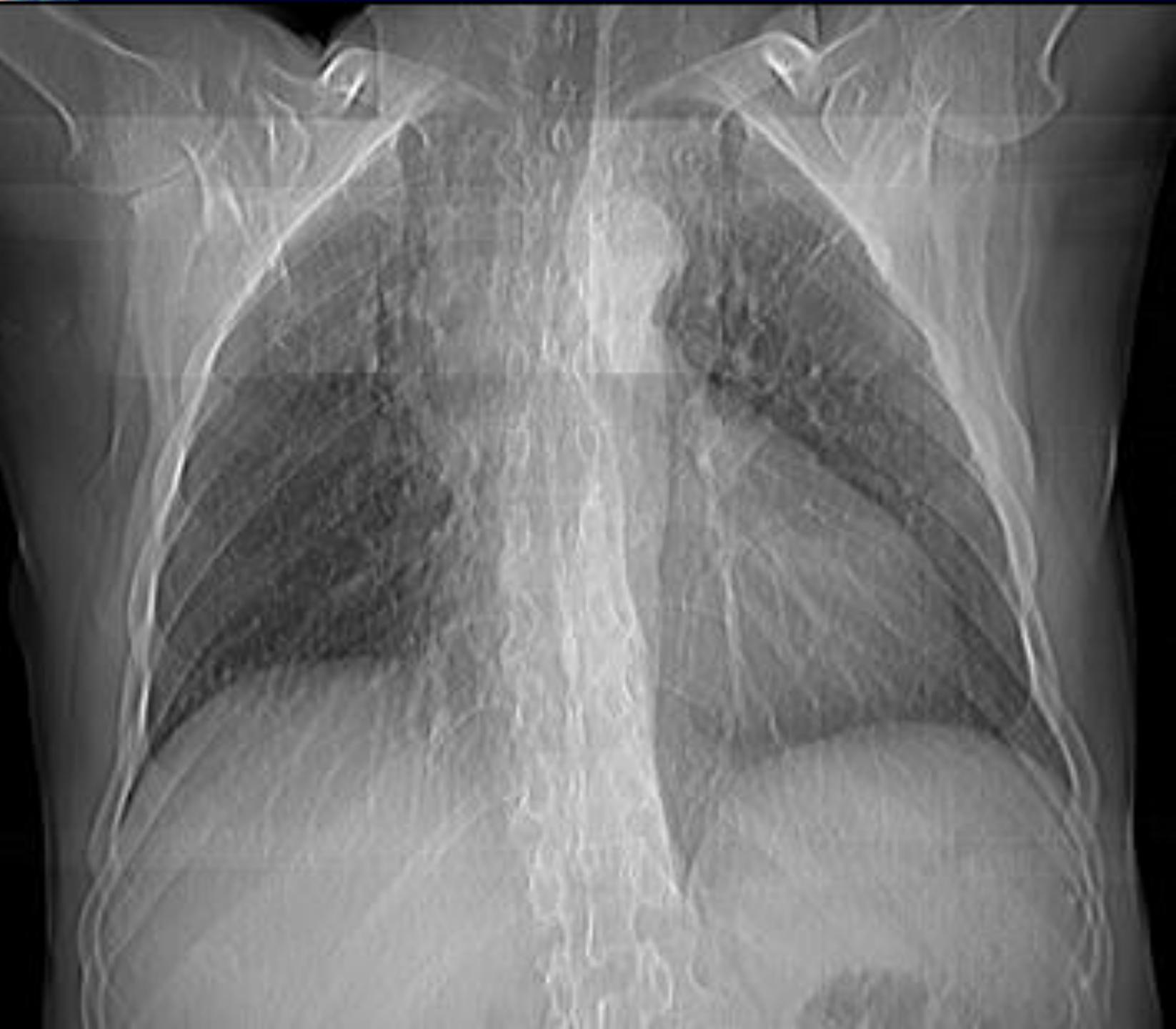
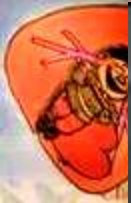
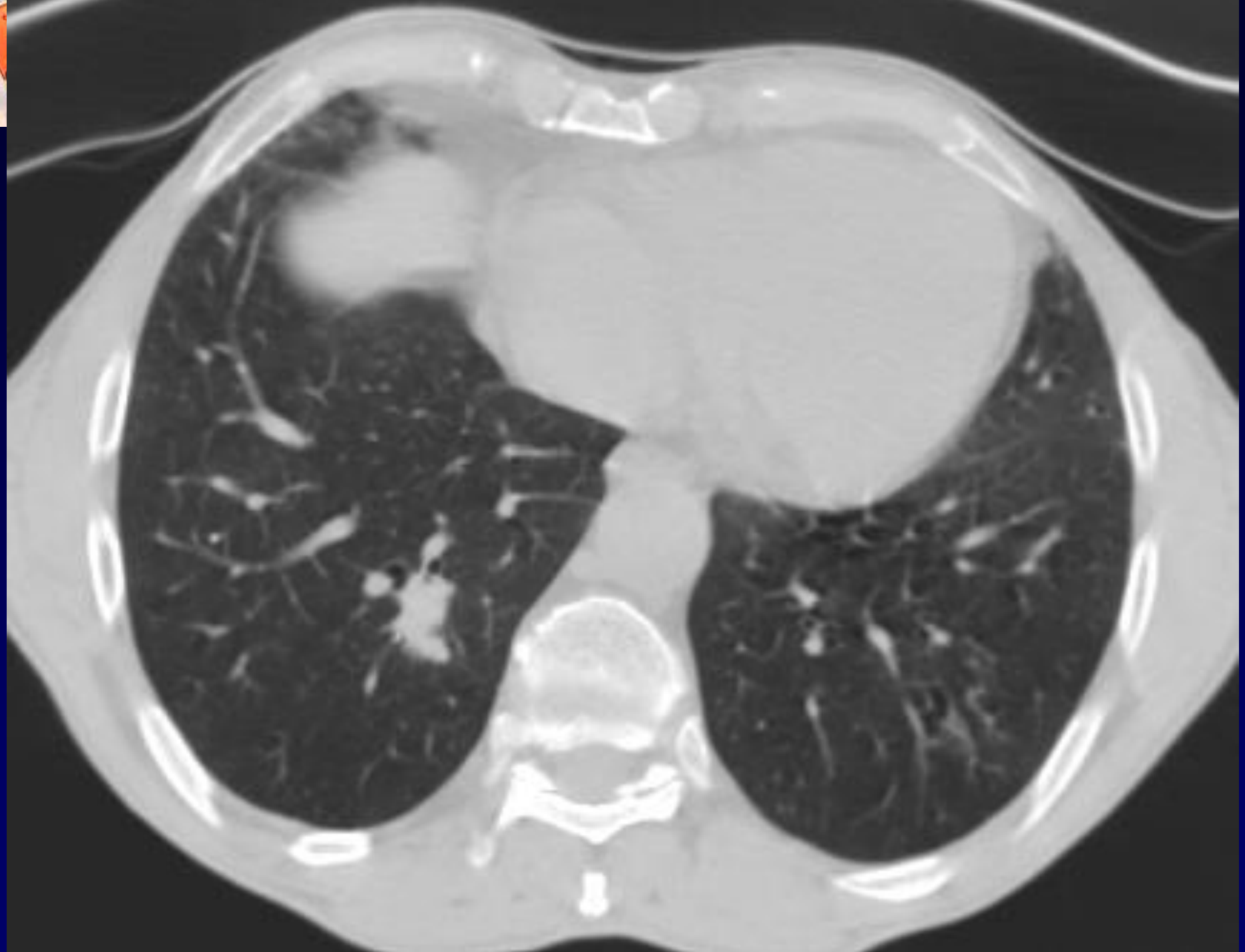**M EL HAJJAM
P LACOMBE**

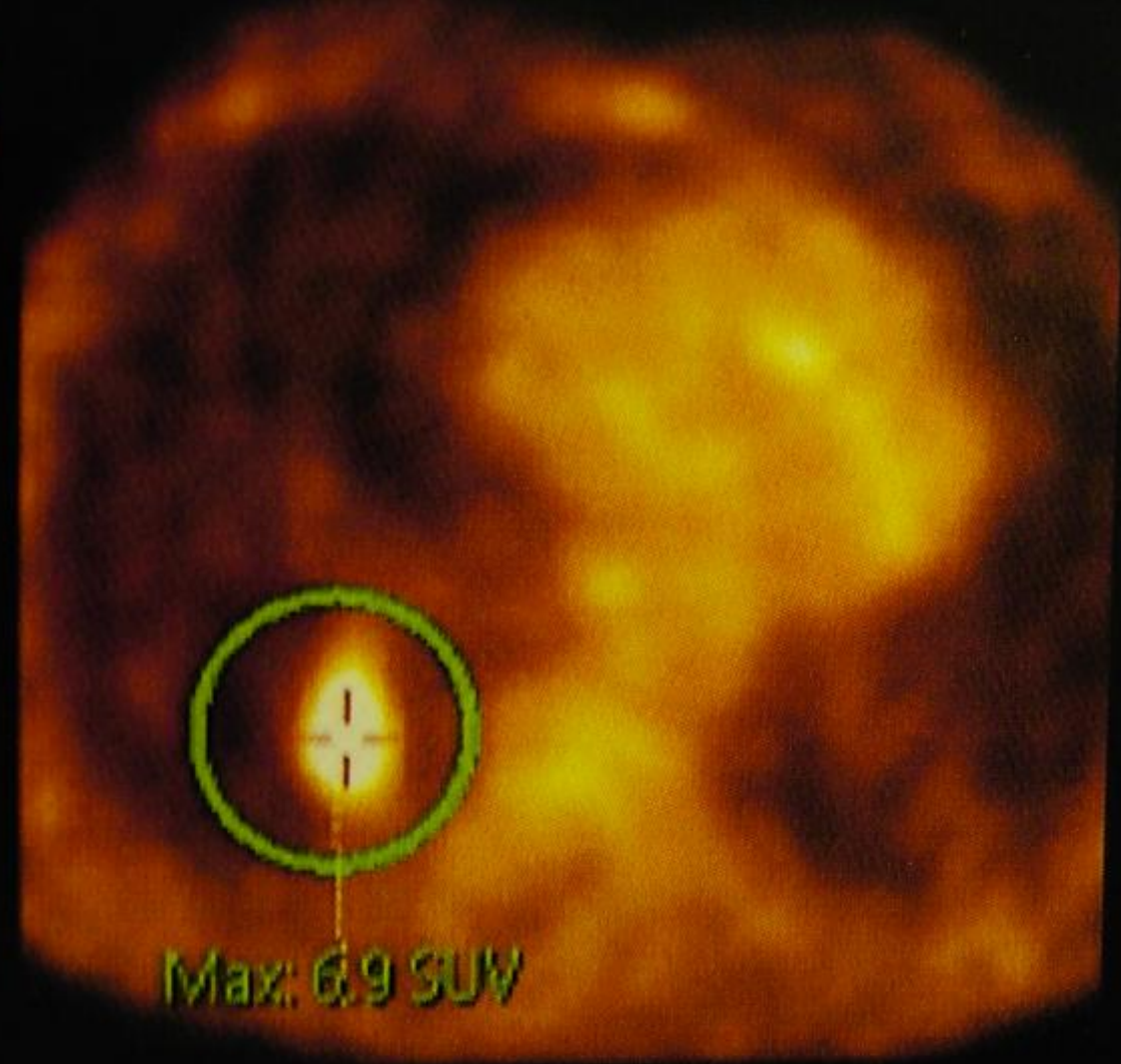
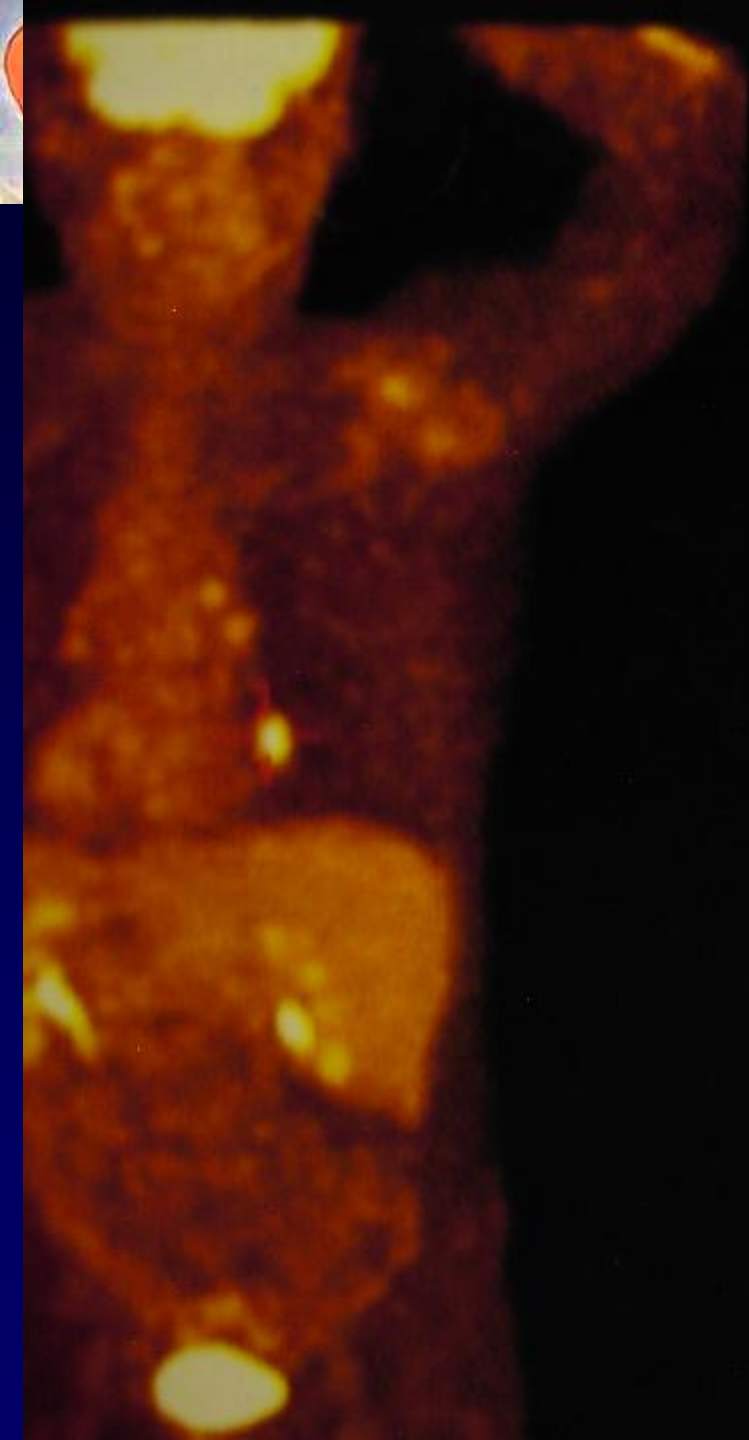
Homme de 69 ans

Tabac = 0

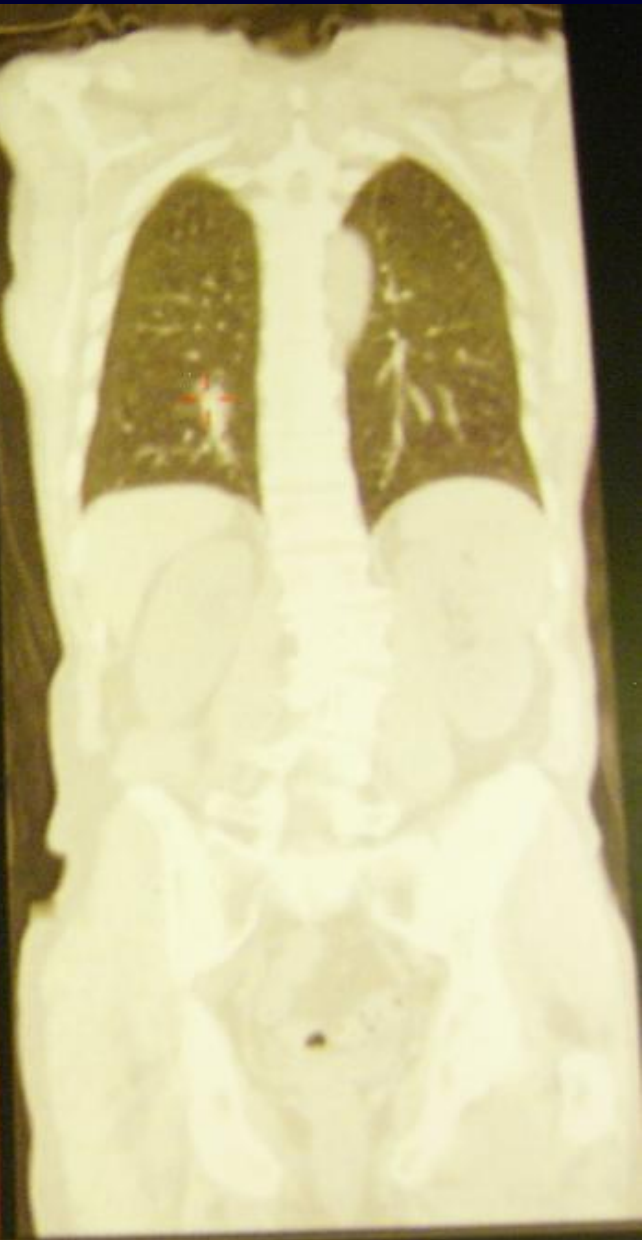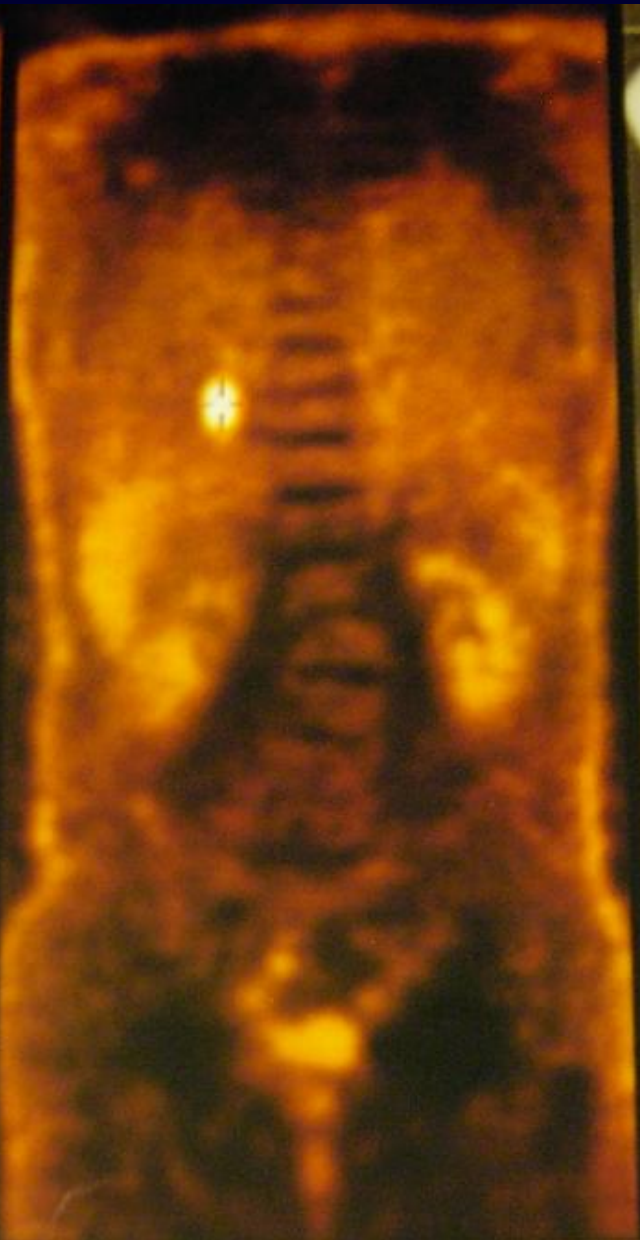
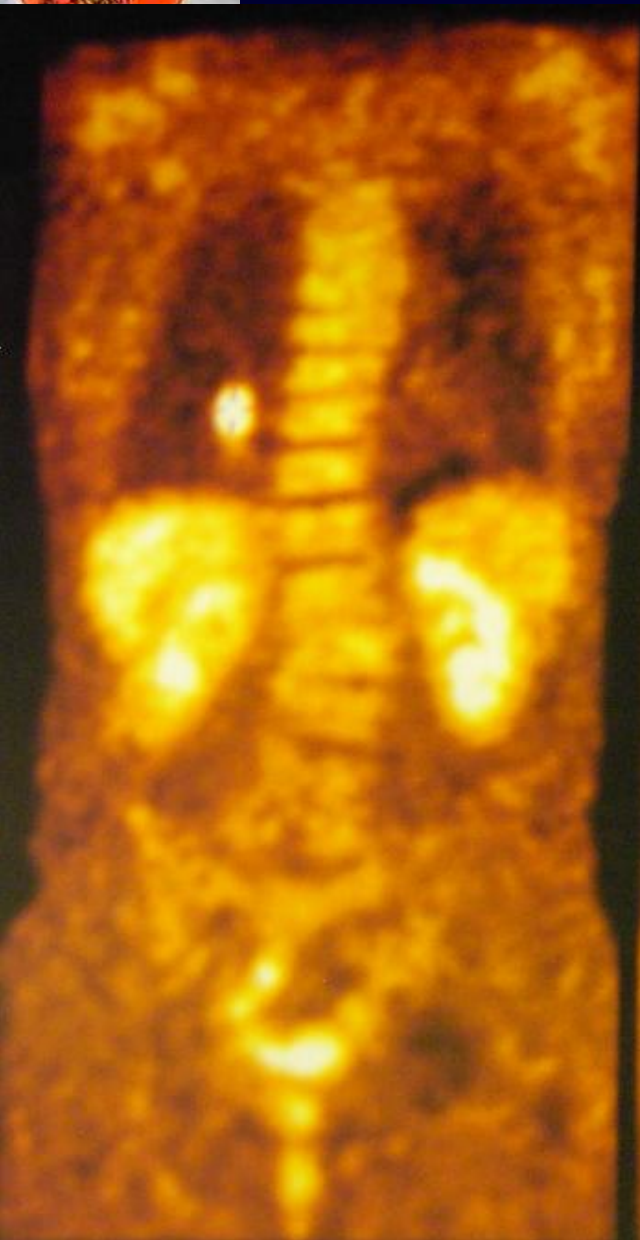**Nodule pulmonaire droit
persistant après une pneumonie**

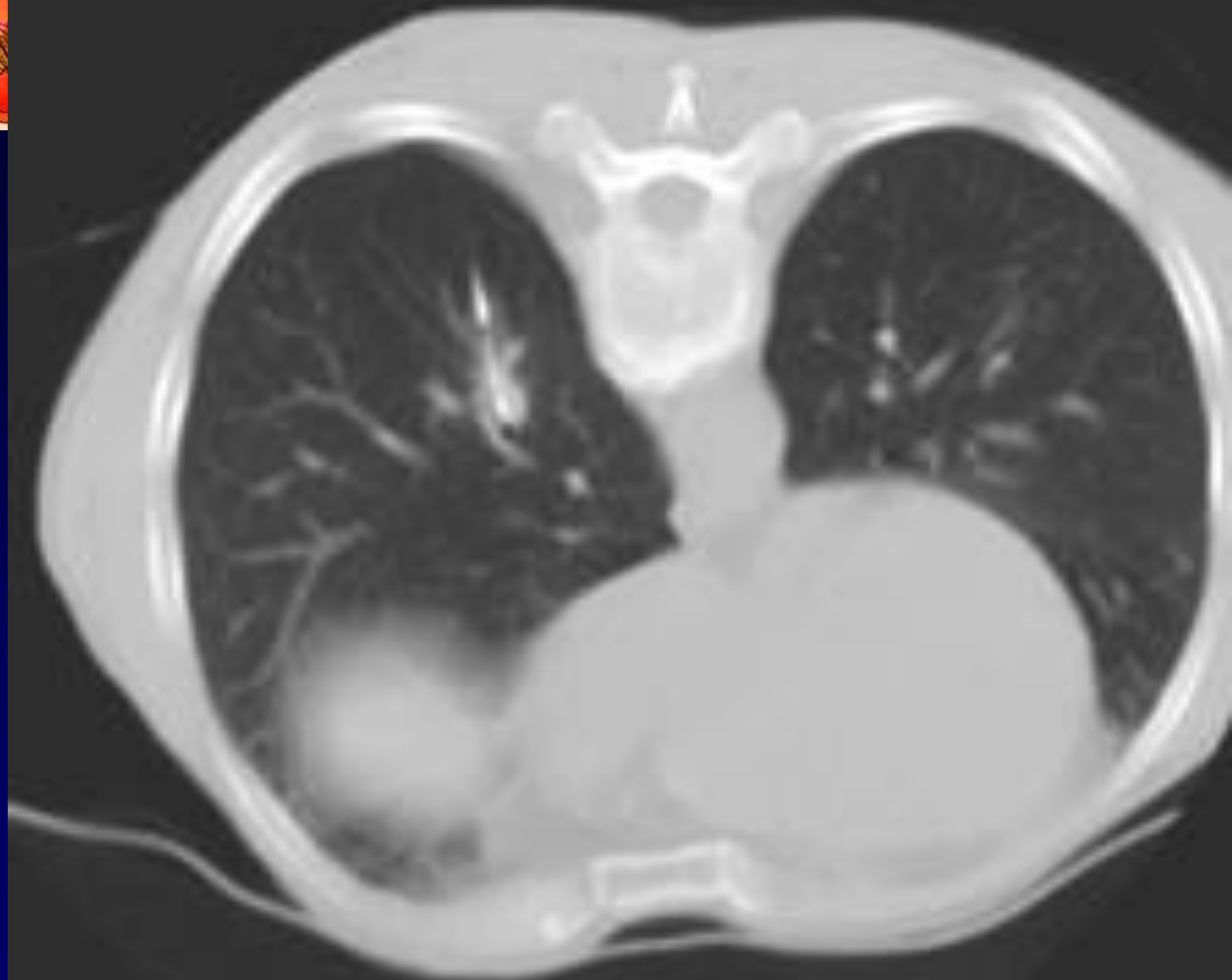

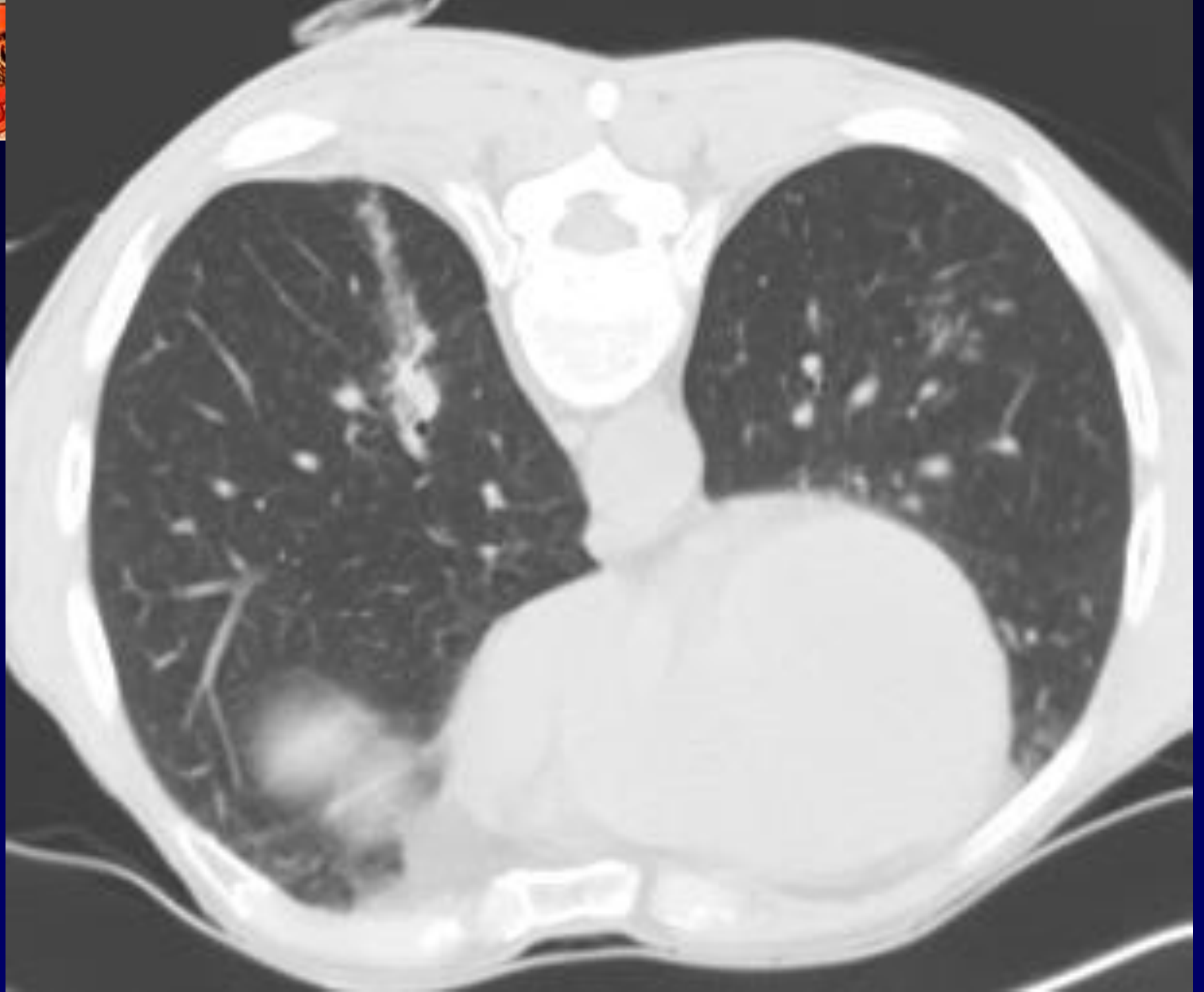

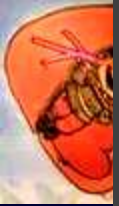


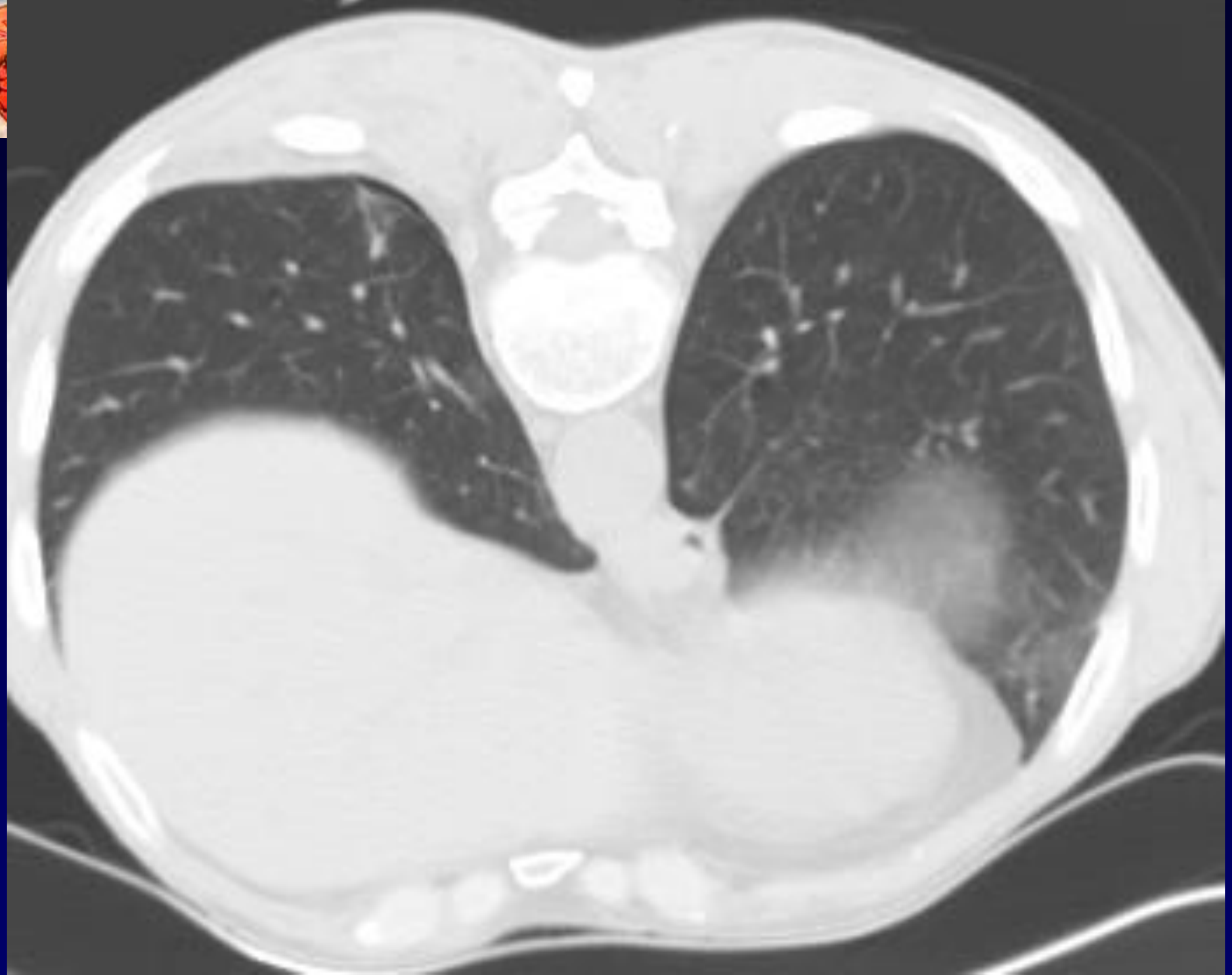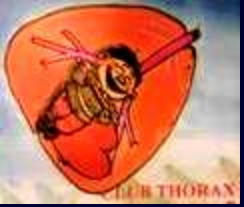Max: 6.9 SUV



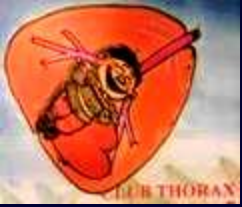







Diagnostic ?

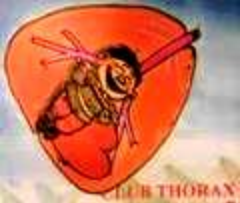

Diagnostic

**Multiples granulomes épithélioïdes
giganto-cellulaires, sans nécrose**

Tuberculose retenue

Trithérapie antibacillaire



Contrôle à 4 mois

